

## When and Who is a Candidate for a Transcatheter Pulmonary Valve?

Aimee K. Armstrong, M.D.  
 University of Michigan Congenital Heart Center  
 C. S. Mott Children's Hospital  
 October 10, 2010

## Disclosures

- No financial disclosures
- Site PI for the Medtronic Melody® Transcatheter Pulmonary Valve Post-Approval Study

## Transcatheter Heart Valves

- Edwards SAPIEN™ Transcatheter Heart Valve
- Medtronic Melody® Transcatheter Pulmonary Valve
  - Only FDA-Approved transcatheter heart valve

## Overview

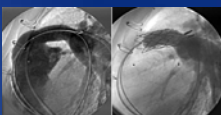
- Overview of the Melody TPV
- Who and When?
- U.S. Melody Valve Trial
- Case Presentation
- U-M Experience

## Melody® Transcatheter Pulmonary Valve

### Intended to:

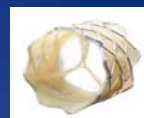- Relieve RV-PA conduit stenosis without inducing regurgitation
- Restore & maintain RV-PA conduit competence

**....with the goal of extending RV to PA conduit life**



## Melody® Transcatheter Pulmonary Valve

- 18mm Modified Contegra Bovine Jugular Vein Valve
- Platinum Iridium Stent
  - 28mm length
  - Crimped down to 6mm, re-expanded 18, 20, or 22-mm



## Medtronic Ensemble® Delivery System

- Proprietary Balloon-In-Balloon (BIB) delivery system
  - Retractable sheath covers Melody® valve once it is crimped over the balloon
- 22Fr size (Outer Diameter)



## Who and When

### Pediatric and adult patients who have:

- A full (circumferential) RVOT conduit that was  $\geq 16$  mm in diameter when originally implanted, AND
- Dysfunctional RVOT conduit with EITHER:
  - Regurgitation: moderate or severe regurgitation, OR
  - Stenosis: mean RVOT gradient  $\geq 35$  mm Hg by echo

## Contraindications

- Venous anatomy cannot accept a 22F introducer
- Obstruction of SVC and IVC
- Active endocarditis

## Off-label Use

- Placement in a bioprosthetic valve  
(i.e. Mitroflow, Mosaic, Hancock)

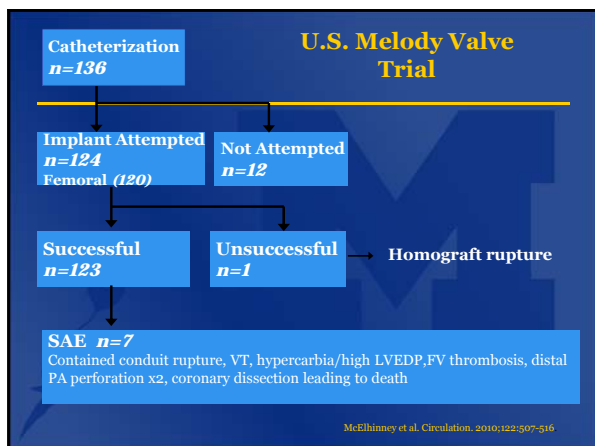
## Melody® TPV Historical Overview

- Sep 2000 1<sup>st</sup> Melody® TPV implant -Paris
- Sep 2005 100<sup>th</sup> patient received a Melody® TPV
- Sep 2006 CE Mark received – 1<sup>st</sup> transcatheter valve commercially available
- Jan 2007 1<sup>st</sup> US implant for IDE study (Boston)
- Jan 2010 FDA Approval under an HDE designation
- April 2010 ~1,350 patients, ~100 implanting centers worldwide
- April 2010 1<sup>st</sup> implants at U-M C.S. Mott Children's Hospital

## U.S. Melody Valve Trial Short & Medium-Term Outcomes

- Multicenter (5) prospective non-randomized study
- January 2007 – August 2009
- 136 patients enrolled
- Median age 19 yrs (7-53 yrs)

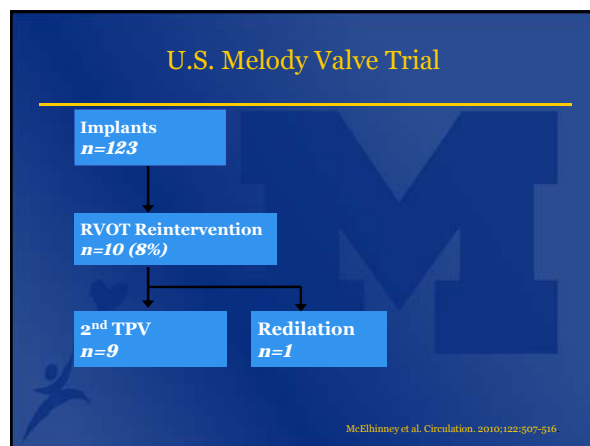
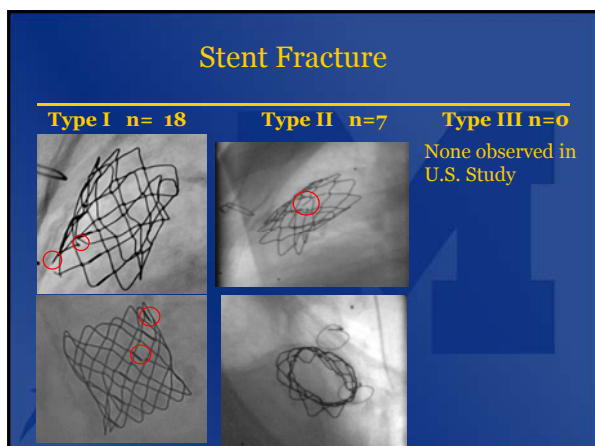
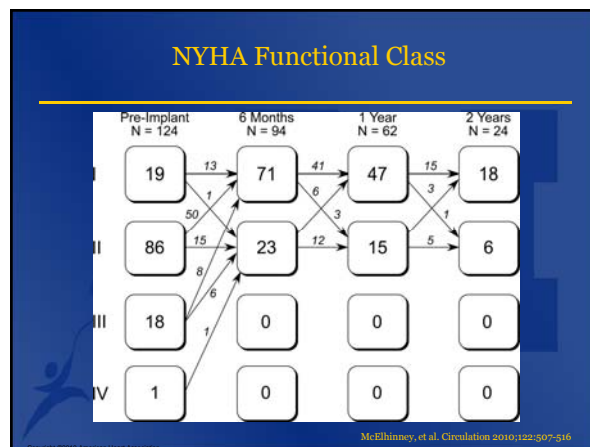
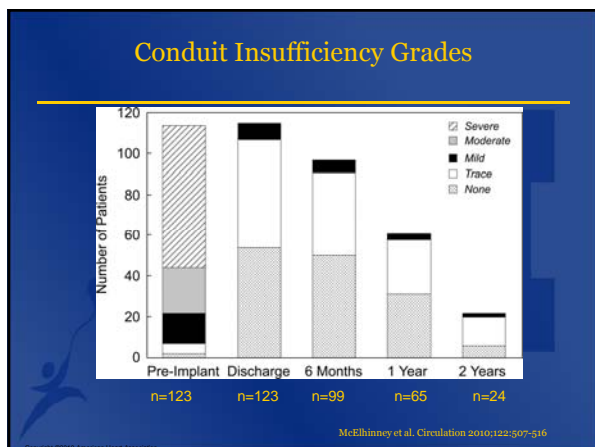
McElhinney et al. Circulation. 2010;122:507-516



### U.S. Melody Valve Trial

	Pre-TPV	Post-TPV
RVOT PSEG (mmHg)	37	12
Moderate or severe PR	81%	0%

McElhinney et al. Circulation. 2010;122:507-516



### Key Findings From Clinical Evidence


---

- High degree of procedural success
- Low incidence of procedural SAE
- Low incidence of device-related SAE
  - Recurrent RVOT obstruction most common AE
  - Usually related to stent fracture & managed with 2<sup>nd</sup> TPV
- Valve competence maintained over follow-up (4 yrs)

### Melody TPV Case

---

- 27 year old
- PA/VSD s/p repair 22 mm pulmonary homograft with 20 mm Dacron extension (1987)
- LPA stent x 2
- Severe conduit stenosis & moderate regurgitation

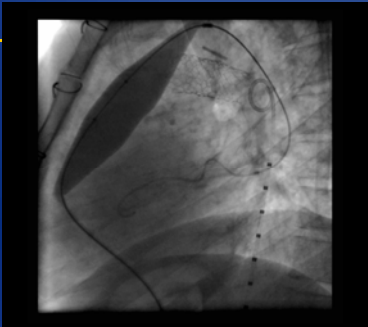


Lossy compression - not intended for diagnosis

### Melody TPV Case

---


- Balloon angioplasty
  - First – low pressure
  - Second – high pressure



### Melody TPV Case

---

- Test occlusion
- Simultaneous coronary angiography




Lossy compression - not intended for diagnosis

### Melody TPV Case

---

- Pre-stenting to decrease risk of Melody TPV fracture




Lossy compression - not intended for diagnosis

### Melody TPV Case

---

- Pre-stenting to decrease risk of Melody TPV fracture




Lossy compression - not intended for diagnosis

**Melody TPV Case**

---

•Melody TPV Implantation

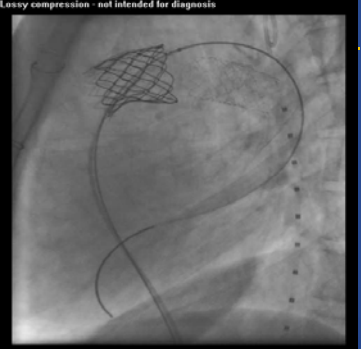


Lossy compression - not intended for diagnosis

**Melody TPV Case**

---

•MPA angiography showing no pulmonary regurgitation




Lossy compression - not intended for diagnosis

**Melody TPV Case**

---

- RV angiography showing no stenosis
- RV pressure 35% of systemic
- PSEG 13 mmHg



Lossy compression - not intended for diagnosis

**Melody Transcatheter Pulmonary Valve**

---

- General anesthesia
- No stitches
- One night hospitalization
- Daily aspirin
- SBE prophylaxis
- Normal activities after 3 days

**U-M Melody Experience**

---

<p><b>Catheterization</b> <i>n=11</i></p> <p>↓</p> <p><b>Implant Attempted</b> <i>n=11</i> Femoral (9) RIJ (2)</p> <p>↓</p> <p><b>Successful</b> <i>n=11</i></p>	<ul style="list-style-type: none"> <li>•Mean age 25 yrs (12-42 yrs)</li> <li>•April-September 2010</li> <li>• 6 TOF/PA</li> <li>• 1 Truncus</li> <li>• 4 Ross</li> <li>•No procedural serious adverse events</li> </ul>
--	---

**U-M Melody Experience**

---

	Pre-TPV	Post-TPV
RVOT PSEG (mmHg)	35	11
Moderate or severe PR	91%	0%

### U-M Melody Experience

- Complications in follow-up (mean 3 mo)
  - 1 patient
    - Panic attacks -> chest CT 3 weeks after implant with small distal PE
    - Occluded right common femoral artery from Perclose, requiring surgery
    - Type 1 stent fracture
  - No re-intervention
  - No more than mild PI and mild PS

### Melody<sup>®</sup> TPV Post-Approval Study

- Non-randomized, prospective, multi-center study
- U.S. only
- 10 study centers
- 100 subjects
  - Consented for 5 year follow-up
  - Targeting 10 per study center
- Objective
  - To confirm that the short-term hemodynamic effectiveness in 10 US centers is equivalent to the historical control established in the IDE study
- Primary Outcome Measure
  - % of subjects with acceptable TPV function at 6 months

### Summary

#### Who:

- A full (circumferential) RVOT conduit that was  $\geq$  **16 mm** in diameter when originally implanted, AND

#### When:

- Dysfunctional RVOT conduit with EITHER:
  - Regurgitation: moderate or severe regurgitation, OR
  - Stenosis: mean RVOT gradient  $\geq$  35 mm Hg by echo